

Case report

Open Access

## Hepatosolithiasis with biliary ascariasis – a case report

KS Pilankar<sup>1</sup>, AD Amarapurkar\*<sup>1</sup>, RM Joshi<sup>2</sup>, TS Shetty<sup>2</sup>, AS Khithani<sup>2</sup> and VV Chemburkar<sup>3</sup>

Address: <sup>1</sup>Department of Pathology, B Y L Nair Charitable Hospital and T N Medical College, Mumbai, India, <sup>2</sup>Department of Surgery, B Y L Nair Charitable Hospital and T N Medical College, Mumbai, India and <sup>3</sup>Department of Radiology, B Y L Nair Charitable Hospital and T N Medical College, Mumbai, India

Email: KS Pilankar - kirtikumarp@yahoo.com; AD Amarapurkar\* - anjali\_1963@hotmail.com; RM Joshi - anjali\_1963@hotmail.com; TS Shetty - tsshetty@rediff.com; AS Khithani - amit\_khithani@yahoo.com; VV Chemburkar - vipulchem@indiatimes.com

\* Corresponding author

Published: 20 December 2003

Received: 23 June 2003

*BMC Gastroenterology* 2003, 3:35

Accepted: 20 December 2003

This article is available from: <http://www.biomedcentral.com/1471-230X/3/35>

© 2003 Pilankar et al; licensee BioMed Central Ltd. This is an Open Access article: verbatim copying and redistribution of this article are permitted in all media for any purpose, provided this notice is preserved along with the article's original URL.

### Abstract

**Background:** Biliary ascariasis is regarded as possible etiological factor for hepatolithiasis. Here we report one case of a patient with hepatolithiasis with biliary ascariasis who developed a liver abscess, which was treated with partial hepatectomy.

**Case presentation:** A young adult female presented with epigastric pain and vomiting with repeated attacks of cholangitis. ERCP showed evidence of multiple intrahepatic calculi with the development of abscess in the left lobe of liver. The patient underwent partial hepatectomy and was found to have biliary ascariasis on histology. She was treated with antihelminthic therapy and has had an uneventful postoperative period of 2 years.

**Conclusion:** Biliary ascariasis with hepatolithiasis, although rare, should be considered in endemic countries.

### Background

Hepatosolithiasis is more prevalent in Asian countries and can be associated with helminthiasis [1,2]. In India biliary ascariasis has been reported as endemic in Kashmir valley [3,4]. Elsewhere in country there are only few reports of biliary ascariasis [5]. We report a patient with a case of hepatolithiasis with ascariasis who developed liver abscess and was treated with surgical resection.

### Case presentation

A 35 year old female presented with dull aching epigastric pain and vomiting for 2 days. There was history of repeated attacks of cholangitis over a 2 year period for which she was being investigated. The patient was averagely built and poorly nourished. Jaundice was present without signs of liver cell failure. Vital parameters were

within normal limits. On investigation, hemoglobin was 10.5 gm%, total WBC count was 18,500 /cmm. Liver function tests showed serum bilirubin 4.8 mg/dl, alkaline phosphatase 24 IU, AST 110 U/L and ALT 86 U/L. Ultrasonography showed right and left intrahepatic calculi with an abscess in left lobe of liver, dilated common bile duct (CBD) and gallstones. CT scan showed an abscess in the left lobe of liver with multiple bilateral intrahepatic calculi (Fig 2 and 3. ERCP revealed dilated CBD, biliary strictures with dilatation of some of the intrahepatic biliary radicals. An attempt was made to remove some of the calculi. In view of hepatolithiasis the patient was taken up for surgery to remove intrahepatic stones, however during surgery segment 2 and 3 were found to be destroyed with abscess. Hence segment 2 and 3 were resected with subtotal excision of CBD and Roux-en-Y hepaticojejunostomy.

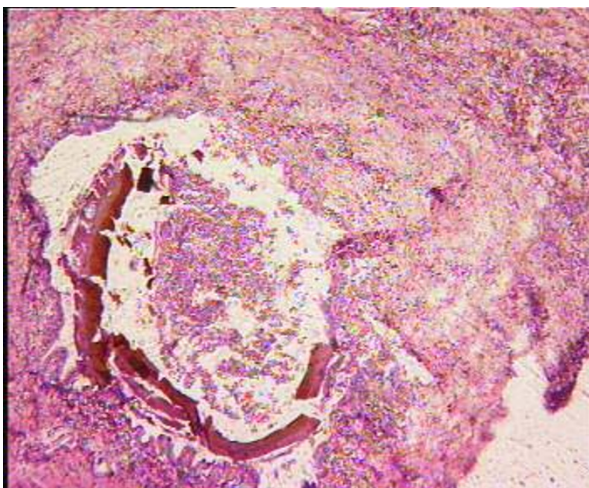
Intraoperatively stones in right hepatic biliary tract were extracted.

Macroscopic examination of left hepatectomy specimen was dark green and measuring 12 cm × 4 cm × 3 cm in dimensions. A localized area of 4 cm × 3 cm × 3 cm was grayish, dull and friable and was interpreted as abscess. The wall of the abscess were irregular, necrotic and smooth at places. Surrounding parenchyma showed dilated biliary radicals, some were impacted with black stones.

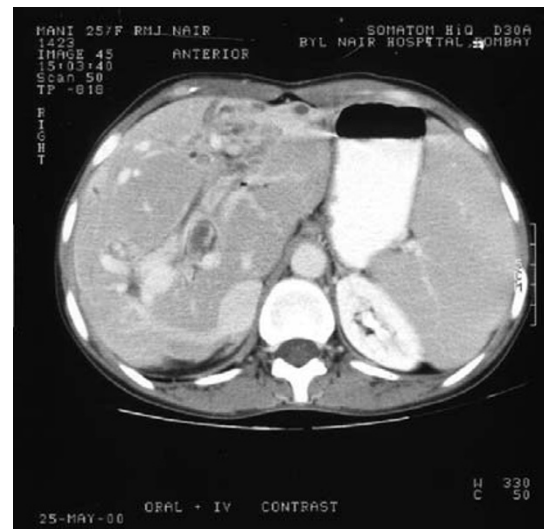Histopathology revealed multiple dilated bile ducts. One of which showed extensive ulceration of mucosa, dense mixed inflammation, filled with bile that was corresponding to an area of abscess. Lumina of some of the larger bile ducts were filled with tubular structures having smooth, long, linear defects with tapering ends that were surrounded by bile sludge and inflammatory cell reaction suggestive of adult helminthes with possibility of ascariasis (fig 1). Surrounding liver showed features of secondary biliary cirrhosis. Postoperative period was uneventful. The patient was given broad-spectrum antihelminthic treatment orally and discharged. She is on regular follow-up for next 2 years without any complications.

## Discussion

Hepatoolithiasis or primary intrahepatic stones are prevalent in the Far East countries such as Japan, Korea, and Taiwan [6]. The relative incidence of hepatolithiasis against all gall stones in western countries is approximately 1%, whereas in Taiwan, South Korea, China it has



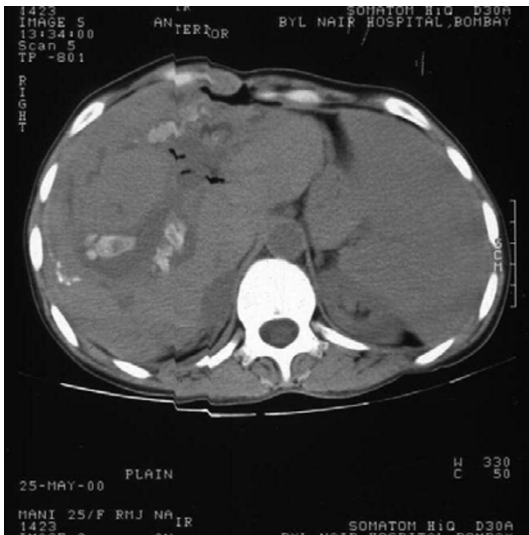
**Figure 1**  
Hematoxylin and eosin section showing dilated bile duct filled with parasite, surrounded by inflammatory reaction. (100×)



**Figure 2**

CT with contrast – Intrahepatic biliary radical dilatation with biliary calcification.

been reported to be 20%, 18%, 38–45% respectively [6]. Biliary ascariasis is a common problem in certain areas of world. Although it is not common in developed countries, with increasing air travel and immigration, one must be aware of this condition. *Ascaris lumbricoides* is a common parasite and over a billion people are estimated to be infested worldwide [5]. It is more common than *Clonorchis sinensis* and other flukes which are associated with cholangiohepatitis. Biliary ascariasis is predominantly a disease of adult women [3]. Duration of symptoms vary from few months to few years. These patients usually present with biliary colic (56%), acute cholangitis (25%), acute cholecystitis (13%), acute pancreatitis (6%) and rarely hepatic abscesses (less than 1%) [4]. Our case also presented with recurrent attacks of cholangitis. Adult forms of *Ascaris lumbricoides* are usually passed into the intestine, however worms in the duodenum and invading the ampulla of Vater usually present as biliary colic or acute pancreatitis due to blocked CBD or pancreatic duct. These worms migrate through CBD, cystic duct and intrahepatic duct leading to biliary colic and cholangitis. Presence of dead worms form nidus for the CBD or hepatic stone formation. Further migration of worms into the intrahepatic duct causes secondary biliary cirrhosis, stricture formation, bile duct stenosis, hepatolithiasis and abscess formation. These worms also have high glucuronidase activity that deconjugates bilirubin and form pigment stones.



**Figure 3**

CT plain – Intrahepatic biliary radical dilatation with biliary calcification.

The diagnosis of hepatolithiasis with ascariasis is usually possible on ultrasonography of the abdomen and ERCP [4]. However in our case intrahepatic calculi were diagnosed on CT scan and ERCP but the presence of parasite (ascariasis) was noticed only after histopathology of the resected specimen. Though ERCP plays a major diagnostic and therapeutic role at times it may not help in the diagnosis of biliary ascariasis. This is due to active movement of the worms, which are going into and out of the biliary tract [4].

The treatment of hepatolithiasis with biliary ascariasis is endoscopic extraction of calculi and worms from the bile duct with or without sphincterotomy which gives immediate relief. However in presence of complications hepatectomy is the only treatment of choice. Sphincterotomy has disadvantages in endemic areas, as these patients are prone to develop remigration of worms into biliary tree. Supportive anthelmintic treatment for long periods is required in these cases. Improvement in sanitation plays crucial role in the epidemiological control of these hepatobiliary diseases.

### Conclusion

Biliary ascariasis with hepatolithiasis, although is rare, should be considered in endemic countries.

### Competing interests

None declared.

### Authors' contributions

Complete workup of the patient was done by surgeons Joshi R M, Shetty T S, Khithani A S Patient was diagnosed as hepatolithiasis with the help of radiologist Chemburkar V V who performed USG, CT Scan. Further histopathology was carried out and this case was diagnosed as hepatolithiasis due to biliary ascariasis by Pilankar K S, Amarapurkar A D.

### Acknowledgements

Written consent was obtained from the patient for the publication of patient's details.

### References

1. Leung JW, Yu AS: **Hepatolithiasis and biliary parasites.** *Baillieres Clin gastroenterol* 1997, **11**:681-706.
2. Yellin AE, Donovan AJ: **Biliary lithiasis and helminthiasis.** *Am J Surg* 1981, **142**(1):128-136.
3. Khuroo MS, Zargar SA: **Biliary ascariasis. A common cause of biliary and pancreatic disease in an endemic area.** *Gastroenterology* 1985, **88**(2):418-423.
4. Khuroo MS, Zargar SA, Mahajan R: **Hepatobiliary and pancreatic ascariasis in India.** *Lancet* 1990, **335**(8704):1503-1506.
5. Mishra SP, Dwivedi M: **Clinical features and management of biliary ascariasis in non-endemic area.** *Postgraduate Med J* 2000, **76**:29-32.
6. Pausawasdi A, Watanapa P: **Hepatolithiasis: epidemiology and classification.** *Hepatogastroenterology* 1997, **44**(14):314-316.

### Pre-publication history

The pre-publication history for this paper can be accessed here:

<http://www.biomedcentral.com/1471-230X/3/35/pre-pub>

Publish with **Bio Med Central** and every scientist can read your work free of charge

"BioMed Central will be the most significant development for disseminating the results of biomedical research in our lifetime."

Sir Paul Nurse, Cancer Research UK

Your research papers will be:

- available free of charge to the entire biomedical community
- peer reviewed and published immediately upon acceptance
- cited in PubMed and archived on PubMed Central
- yours — you keep the copyright

Submit your manuscript here:  
[http://www.biomedcentral.com/info/publishing\\_adv.asp](http://www.biomedcentral.com/info/publishing_adv.asp)

