

CASE REPORT

Open Access



# Sweet's syndrome and mucosal prolapse polyps in a male patient with ulcerative colitis

Xixian Zhao<sup>1,2†</sup>, Si Jiang<sup>3†</sup>, Yanan Chen<sup>1,2</sup>, Jialong Liu<sup>1,2</sup>, Jing Liu<sup>1,2\*</sup> and Xianyan Shi<sup>1,2\*</sup>

## Abstract

**Background:** Sweet's syndrome (SS), also known as acute febrile neutrophilic dermatosis, is a rare neutrophilic dermatitis characterized by pyrexia, neutrophilia and painful papulonodular lesions with a neutrophilic dermal infiltrate.

**Case presentation:** We presented a case report of classical SS associated with ulcerative colitis (UC) and mucosal prolapse polyps (MPPs) in a male patient.

**Conclusions:** The particularity of this case is the occurrence of MPPs in a male patient with UC and classical SS. We also discussed whether this patient with concurrent Epstein–Barr virus infection could be treated with corticosteroids.

**Keywords:** Classical Sweet's syndrome, Ulcerative colitis, Mucosal prolapse polyps, Corticosteroids

## Background

Ulcerative colitis (UC) is an idiopathic, chronic inflammatory disorder characterized by relapsing and remitting mucosal inflammation in colorectal mucosa [1, 2]. Diagnosis of UC is based on clinical symptoms, endoscopic and pathological features. The main symptoms of UC include bloody diarrhea, rectal bleeding, urgency, tenesmus, fecal incontinence, abdominal pain and fever [3]. Almost 50% of UC patients will develop extraintestinal manifestations during their lifetime [4]. Skin manifestations, such as pyoderma gangrenosum, bowel-associated dermatosis–arthritis syndrome, aseptic abscess ulcers, pyodermatitis–pyostomatitis vegetans and Sweet's syndrome (SS), could be found in UC [5–8]. SS, as a rare skin manifestation, needs to be diagnosed promptly to avoid life-threatening conditions [9]. We reported the first case of a male with classical SS associated with UC and mucosal prolapse polyps (MPPs).

## Case presentation

A 31-year-old man with UC was presented to a local hospital due to diarrhea and hematochezia. The young man was diagnosed with UC 3 years ago but didn't receive regular treatment as prescribed. After the treatment of mesalazine, anti-infection medicines of amoxicillin, parenteral nutrition supplementation and protecting the intestinal mucosa, all the symptoms worsened, and the patient began to develop fever and facial erythema with blisters forming at the raised border of the erythema (Fig. 1a, b). For further treatment, the patient was referred to our hospital with the complaints of bloody purulent stool for 1 month, fever for 9 days, erythema and blisters on face for 7 days. The initial laboratory examination demonstrated an elevated white blood cell count ( $10.60 \times 10^9/\mu\text{L}$ , normal range  $3.5\text{--}9.5 \times 10^9/\mu\text{L}$ ), increased C-reactive protein (173.96 mg/L, normal range 0–10 mg/L), procalcitonin (1.93 ng/mL, normal range < 0.05 ng/mL) and Epstein-Barr virus (EBV) DNA (1720 copies/mL, normal range 0 copies/mL) levels, together with a low haemoglobin (90.00 g/L, normal range 130–175 g/L) level. The computed tomography with contrast medium exhibited extensive colonic wall thickening with a few perienteral exudative changes and multiple lymph nodes in the retroperitoneal and

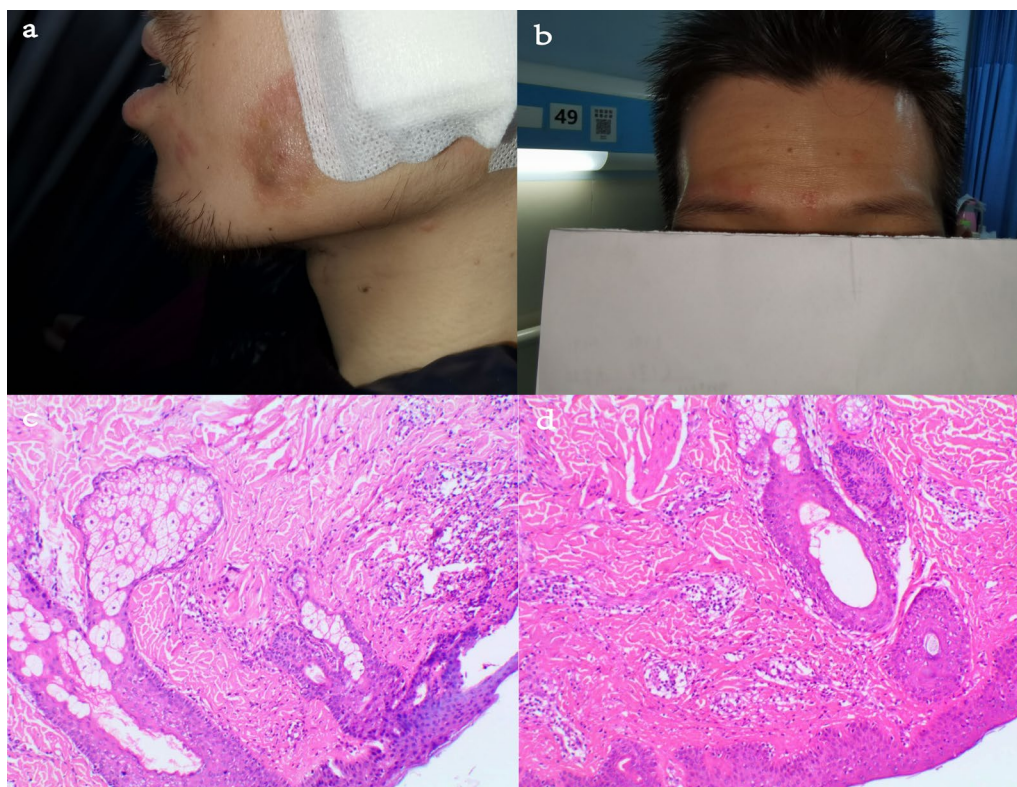
\*Correspondence: liujing\_Gl@whu.edu.cn; xianyan.shi@163.com

<sup>†</sup>Xixian Zhao and Si Jiang contributed equally to this work.

<sup>1</sup> Department of Gastroenterology, Zhongnan Hospital of Wuhan University, No. 169, Donghu Road, Wuchang District, Wuhan 430071, Hubei Province, China

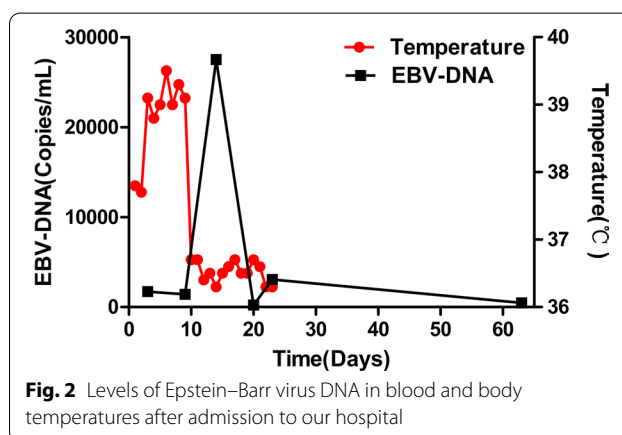
Full list of author information is available at the end of the article





**Fig. 1** a, b Sweet's syndrome skin lesions in this patient with classical Sweet's syndrome. c, d Histologic findings for the skin lesions showing localized epidermal ulceration with neutrophil infiltration and dermal appendages with the infiltration of chronic inflammatory cells and neutrophils (H&E stain)

mesangial areas, consistent with the characteristics of UC. Computed Tomographic Enterography showed extensive colonic thickening wall with a few perienteric exudative inflammation, and multiple lymph nodes in retroperitoneal and mesangial areas, which were consistent with the characteristics of UC. Biopsies of cutaneous lesions were performed, revealing localized epidermal ulceration with neutrophil infiltration and dermal appendages with the infiltration of chronic inflammatory cells and neutrophils (Fig. 1c, d). We considered the clinical diagnosis of acute febrile neutrophilic dermatosis. After ruling out other infectious diseases and lymphoproliferative syndrome, we decided to initiate corticosteroid treatment though high levels of EBV DNA. After that, the patient no longer developed fever and the skin manifestations improved significantly (Fig. 2). Colonoscopy revealed scatter polypoid hyperplasia from the ascending colon to the sigmoid colon (Fig. 3a, b). Histology of the resected polyp was characterized by crypt dilatation, branching, twisting with interstitial edema, local interstitial fibrosis, and muscle fiber penetration growth. And localised neutrophils infiltrated into the epithelium to form cryptonitis. These histological results were

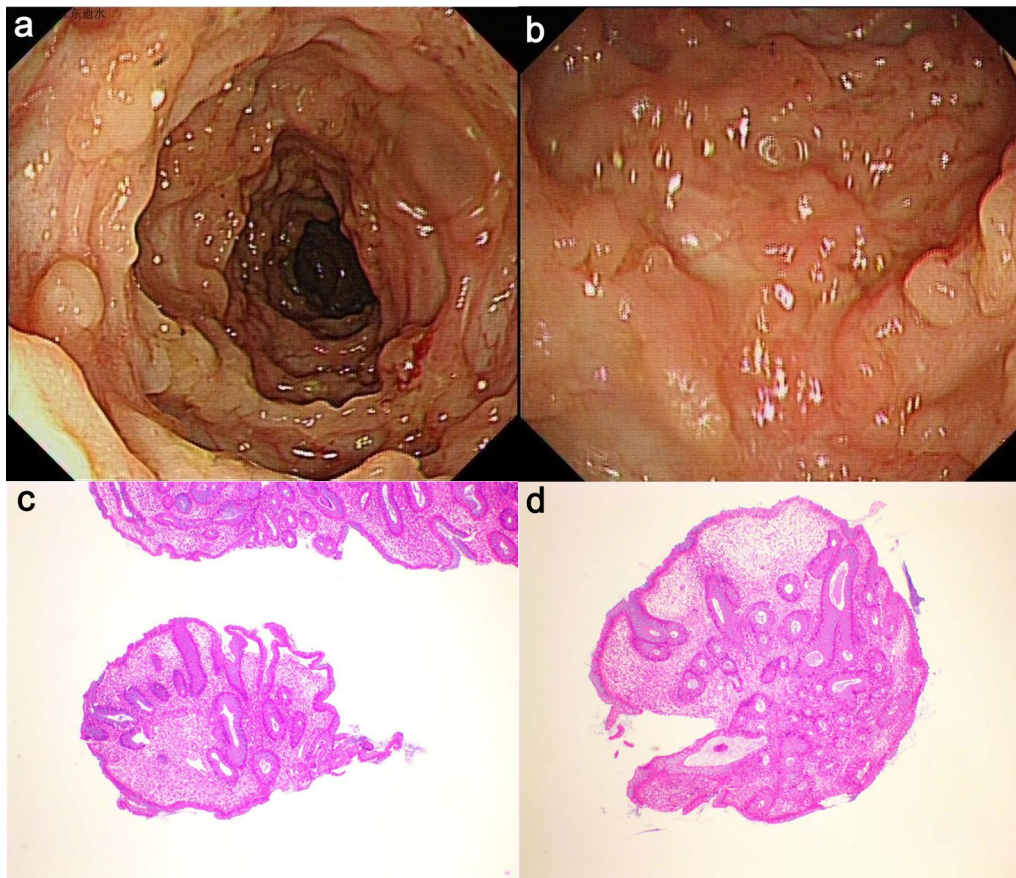


**Fig. 2** Levels of Epstein–Barr virus DNA in blood and body temperatures after admission to our hospital

consistent with the characteristics of MPPs (Fig. 3c, d). No recurrence of SS occurred within 3 months.

**Discussion and conclusion**

Classical SS, which is a subtype of SS, can be idiopathic and associated with inflammatory bowel diseases (IBDs), infections or drug intake [10]. SS may be associated with



**Fig. 3** **a, b** Colonoscopic findings for the mucosal prolapse polyps showing scatter polypoid hyperplasia from the ascending colon to the sigmoid colon. **c, d** Histologic findings for the mucosal prolapse polyps showing crypt dilatation, branching, twisting with interstitial edema, local interstitial fibrosis, muscle fiber penetration growth, and localised neutrophils infiltrated into the epithelium to form cryptonitis (H&E stain)

Crohn's disease [11], and in our report, a case of classical SS associated with UC was presented. The patient was diagnosed with Classic SS based on the criteria recommended in the guidelines, including two major criteria: (1) Abrupt onset of painful erythematous plaques or nodules; and (2) Histopathologic evidence of a dense neutrophilic infiltrate without evidence of leukocytoclastic vasculitis; as well as four minor criteria: (1) Fever  $> 38\text{ }^{\circ}\text{C}$ ; (2) Associated with inflammatory disease or pregnancy or preceded by upper respiratory infection, gastrointestinal infection, or vaccination; (3) Excellent response to treatment with systemic glucocorticoids or potassium iodide; and (4) Abnormal laboratory values at presentation (three of four of the following): a. Erythrocyte sedimentation rate  $> 20\text{ mm/h}$ ; b. Positive C-reactive protein; c.  $> 8000$  leukocytes per microliter; and d.  $> 70\%$  neutrophils [12]. If the patients with UC develop skin symptoms, the skin manifestations of UC, such as pyoderma gangrenosum, SS, bowel-associated dermatosis-arthritis syndrome, aseptic abscess ulcers, and

pyodermitis-pyostomatitis vegetans, must be excluded [13]. Moreover, it is necessary to make a skin biopsy for better diagnosis.

The first-line therapy in classical SS consists of systemic corticotherapy [10], and the second line therapeutic agents can be Cyclosporine, Dapsone, Colchicine or Indomethacin [14–17]. There was also a case in which the patient benefited from tacrolimus therapy but failed to respond to steroids [18]. Though there is evidence that corticosteroid treatment could increase the incidence of EBV infection in patients with UC, this patient needs corticosteroid to control the SS first, which might be fatal [19–21]. Although the load of EBV DNA in the blood was elevated during the administration of corticosteroid, EBV DNA finally turned negative in this case due to its self-limiting feature (Fig. 2).

Some cases of SS in UC have been reported in the literatures. However, there were few reports of colonic MPPs in patients with SS and UC. SS in UC may be associated with flare-ups of UC in most cases,



but sometimes occurred in inactive UC [22–24]. Skin lesions of SS are believed to share common pathogenic mechanisms with the underlying intestinal disease in IBDs. MPPs are rare inflammatory lesions which are part of the mucosal prolapse syndrome [25, 26]. MPPs were considered to be associated with UC [27]. So far, no malignant transformation of MPPs has been reported, and no consensus has been reached on the standard treatment of MPPs as well. The clinical importance of MPPs lies in the fact that they may lead to recurrence, intestinal hemorrhage or obstructive symptoms, in which hence surgical resection is a reasonable option. Since this patient did not have such symptoms at present, we chose regular follow-up monitoring. This patient requires regular colonoscopy to monitor UC and MPPs.

This is a rare case of SS associated with UC and MPPs in a young male. We emphasized the importance of skin biopsy in dermatological manifestations of UC. Systemic corticosteroids are an effective treatment for SS associated with UC though the elevated EBV DNA load in the blood. Colonoscopy should be performed regularly to monitor the UC and MPPs.

#### Abbreviations

SS: Sweet's syndrome; MPPs: Mucosal prolapse polyps; UC: Ulcerative colitis; IBD: Inflammatory bowel disease; EBV: Epstein–Barr virus.

#### Acknowledgements

We thank all doctors and nurses who had participated in the treatment of this patient.

#### Authors' contributions

X.X.Z drafted the manuscript. X.X.Z, S.J, Y.N.C and J.L.L collected the data and reviewed the literature. X.Y.S performed the coloscopy. J.L and X.Y.S drafted the work or substantively revised the manuscript. All of the authors confirmed and approved the final manuscript.

#### Funding

This work was supported by funds from the National Natural Science Foundation of China (J.L., No. 81472735, No. 81101508); National Basic Research Program of China (973program, J.L., No. 2015CB932600); Wuhan University [J.L.] and Zhongnan Hospital of Wuhan University [J.L.], which supported the design of the study and collection, analysis, and interpretation of data and writing the manuscript.

#### Availability of data and materials

All data generated or analysed during this study are included in this published article.

#### Declarations

##### Ethics approval and consent to participate

Not applicable.

##### Consent for publication

Written informed consent was obtained from the patient for publication of this case report and its accompanying images.

##### Competing interests

The authors declare no competing interests.

#### Author details

<sup>1</sup>Department of Gastroenterology, Zhongnan Hospital of Wuhan University, No. 169, Donghu Road, Wuchang District, Wuhan 430071, Hubei Province, China. <sup>2</sup>Hubei Clinical Center and Key Lab of Intestinal and Colorectal Diseases, Wuhan 430071, China. <sup>3</sup>Department of Dermatology and Venereology, Zhongnan Hospital of Wuhan University, Wuhan 430071, China.

Received: 12 July 2021 Accepted: 3 December 2021

Published online: 16 December 2021

#### References

- Ordás I, Eckmann L, Talamini M, Baumgart DC, Sandborn WJ. Ulcerative colitis. *Lancet* (London, England). 2012;380(9853):1606–19.
- Adams SM, Bornemann PH. Ulcerative colitis. *Am Fam Physician*. 2013;87(10):699–705.
- Greuter T, Navarini A, Vavricka SR. Skin manifestations of inflammatory bowel disease. *Clin Rev Allergy Immunol*. 2017;53(3):413–27.
- Vavricka SR, Brun L, Ballabeni P, Pittet V, Prinz Vavricka BM, Zeitz J, Rogler G, Schoepfer AM. Frequency and risk factors for extraintestinal manifestations in the Swiss inflammatory bowel disease cohort. *Am J Gastroenterol*. 2011;106(1):110–9.
- Ahn C, Negus D, Huang W. Pyoderma gangrenosum: a review of pathogenesis and treatment. *Expert Rev Clin Immunol*. 2018;14(3):225–33.
- Aounallah A, Zerriaa S, Ksaa M, Jaziri H, Boussofara L, Ghariani N, Mokni S, Saidi W, Sriha B, Belajouza C, et al. Bowel-associated dermatosis-arthritis syndrome during ulcerative colitis: a rare extra-intestinal sign of inflammatory bowel disease. *Ann Dermatol Venereol*. 2016;143(5):377–81.
- Yamaguchi Y, Nakagawa M, Nakagawa S, Nagao K, Inoue S, Sugiyama T, Izaawa S, Hijikata Y, Ebi M, Funaki Y, et al. Rapidly progressing aseptic abscesses in a patient with ulcerative colitis. *Intern Med* (Tokyo, Japan). 2021;60(5):725–30.
- Dodd EM, Howard JR, Dulaney ED, Rosenthal SI, Wanna MR, Farah RS. Pyodermitis-pyostomatitis vegetans associated with asymptomatic inflammatory bowel disease. *Int J Dermatol*. 2017;56(12):1457–9.
- Ytting H, Vind I, Bang D, Munkholm P. Sweet's syndrome—an extraintestinal manifestation in inflammatory bowel disease. *Digestion*. 2005;72(2–3):195–200.
- Cohen PR. Sweet's syndrome—a comprehensive review of an acute febrile neutrophilic dermatosis. *Orphanet J Rare Dis*. 2007;2:34.
- Catalán-Serra I, Martín-Moraleda L, Navarro-López L, Gil-Borrás R, Pont-Sanjuán V, Ferrando-Marco J, Herrera-García L, Durbán-Serrano L, Hontangas-Pla V, Benlloch-Pérez S, et al. Crohn's disease and Sweet's syndrome: an uncommon association. *Revista española de enfermedades digestivas : organo oficial de la Sociedad Española de Patología Digestiva*. 2010;102(5):331–7.
- Heath MS, Ortega-Loayza AG. Insights into the pathogenesis of Sweet's syndrome. *Front Immunol*. 2019;10:414.
- Antonelli E, Bassotti G, Tramontana M, Hansel K, Stingeni L, Ardizzone S, Genovese G, Marzano AV, Maconi G. Dermatological manifestations in inflammatory bowel diseases. *J Clin Med*. 2021;10(2):364.
- Yasuda F, Fujio Y, Kakuta R, Funakoshi T, Amagai M, Ohyama M. Use of cyclosporin A for successful management of steroid-resistant Sweet's syndrome patient with possible myelodysplastic syndrome. *J Dermatol*. 2014;41(5):465–6.
- Hrin ML, Feldman SR, Huang WW. Dapsone as corticosteroid-sparing therapy for Sweet syndrome. *J Am Acad Dermatol*. 2021. <https://doi.org/10.1016/j.jaad.2021.02.067>.
- Cohen PR. Neutrophilic dermatoses: a review of current treatment options. *Am J Clin Dermatol*. 2009;10(5):301–12.
- De Donno A, von den Driesch P. Akute febrile neutrophile Dermatose (Sweet-Syndrom)—Eine seltene Komplikation der Colitis ulcerosa.
- Fellermann K, Rudolph B, Witthöft T, Herrlinger KR, Tronnier M, Ludwig D, Stange EF. Sweet syndrome and erythema nodosum in ulcerative colitis, refractory to steroids: successful treatment with tacrolimus. *Medizinische Klinik (Munich, Germany)*. 1983. 2001;96(2):105–8.
- Epple HJ. Therapy- and non-therapy-dependent infectious complications in inflammatory bowel disease. *Dig Dis* (Basel, Switzerland). 2009;27(4):555–9.

20. Ciccocioppo R, Mengoli C, Betti E, Comolli G, Cassaniti I, Piralla A, Kruzliak P, Caprnda M, Pozzi L, Corazza GR, et al. Human Cytomegalovirus and Epstein-Barr virus specific immunity in patients with ulcerative colitis. *Clin Exp Med*. 2021;21(3):379–88.
21. Xu S, Chen H, Zu X, Hao X, Feng R, Zhang S, Chen B, Zeng Z, Chen M, Ye Z, et al. Epstein-Barr virus infection in ulcerative colitis: a clinicopathologic study from a Chinese area. *Ther Adv Gastroenterol*. 2020;13:1756284820930124.
22. Shin OR, Lee YH, Bak SH, Cho YS. Gastroenterology: Sweet's syndrome in a patient with acutely exacerbated ulcerative colitis. *J Gastroenterol Hepatol*. 2015;30(6):965.
23. Travis S, Innes N, Davies MG, Daneshmend T, Hughes S. Sweet's syndrome: an unusual cutaneous feature of Crohn's disease or ulcerative colitis. The South West Gastroenterology Group. *Eur J Gastroenterol Hepatol*. 1997;9(7):715–20.
24. Esposito I, Fossati B, Peris K, De Simone C. A rare case of bullous Sweet's syndrome in a patient with inactive ulcerative colitis. *J Eur Acad Dermatol Venereol JEADV*. 2019;33(10):e380–1.
25. Currais P, Pereira da Silva J, Castela J, Marques I, Pereira AD. A rare form of colonic polypoid lesions: prolapsing mucosal syndrome. *Gastrointest Endosc*. 2020;92(5):1132–3.
26. Tendler DA, Aboudola S, Zacks JF, O'Brien MJ, Kelly CP. Prolapsing mucosal polyps: an underrecognized form of colonic polyp—a clinicopathological study of 15 cases. *Am J Gastroenterol*. 2002;97(2):370–6.
27. Aust DE, Rüschoff J. Polyps of the colorectum: non-neoplastic and non-hamartomatous. *Pathologie*. 2011;32(4):297–302.

### Publisher's Note

Springer Nature remains neutral with regard to jurisdictional claims in published maps and institutional affiliations.

Ready to submit your research? Choose BMC and benefit from:

- fast, convenient online submission
- thorough peer review by experienced researchers in your field
- rapid publication on acceptance
- support for research data, including large and complex data types
- gold Open Access which fosters wider collaboration and increased citations
- maximum visibility for your research: over 100M website views per year

At BMC, research is always in progress.

Learn more [biomedcentral.com/submissions](https://biomedcentral.com/submissions)

