

Case report

Open Access

Dieulafoy's lesion of duodenum: a case report

Mohammed Ibrarullah and Gajanan D Waghlikar*

Address: Dept. of Gastroenterology, Sri Venkateswara Institute of Medical Sciences Tirupati 517507 (AP), India

Email: Mohammed Ibrarullah - m_ibrarullah@yahoo.co.in; Gajanan D Waghlikar* - drgajanan2002@yahoo.com

* Corresponding author

Published: 31 January 2003

Received: 17 November 2002

BMC Gastroenterology 2003, **3**:2

Accepted: 31 January 2003

This article is available from: <http://www.biomedcentral.com/1471-230X/3/2>

© 2003 Ibrarullah and Waghlikar; licensee BioMed Central Ltd. This is an Open Access article: verbatim copying and redistribution of this article are permitted in all media for any purpose, provided this notice is preserved along with the article's original URL.

Abstract

Background: Dieulafoy's lesion is an uncommon but important cause of recurrent upper gastrointestinal bleeding. Extragastric location of Dieulafoy's lesion is rare. We report two cases of Dieulafoy's lesion of the duodenum and discuss the management of this extremely uncommon entity.

Case presentation: Two cases of massive upper gastro-intestinal bleeding in young adults due to Dieulafoy's lesion of the duodenum are reported. Endoscopic diagnosis was possible in both cases. Hemostasis was achieved successfully by endoscopic adrenaline injection. The endoscopic appearance, pitfalls in the diagnosis and management of this rare lesion are discussed.

Conclusions: Endoscopic diagnosis of extragastric Dieulafoy's lesion can be difficult because of the small size and obscure location of the lesion. Increased awareness and careful and early endoscopic evaluation following the bleeding episode are the key to accurate diagnosis. Adrenaline injection is one of the important endoscopic modalities for control of bleeding.

Background

Dieulafoy's lesion (DL) is an uncommon but important cause of gastrointestinal (GI) bleeding in which hemorrhage occurs from a pinpoint nonulcerated arterial lesion [1]. While the great majority of DL are located in the stomach within 6 cm of the gastro-esophageal junction the same occurring in other parts of the GI tract is rare [1-3]. We report two cases of recurrent massive upper GI bleeding from DL in duodenum. The endoscopic appearance, pitfalls in the diagnosis of this lesion and its management have been discussed in this report.

Case Presentation

Case 1

A 31-year-old male presented with two episodes of hematemesis over 48 hours duration. Patient had been diagnosed to have duodenal ulcer by an upper GI endoscopy which had been performed two years back for dyspeptic

symptoms. The ulcer had subsequently healed after medical management. There was no history of alcohol abuse or intake of NSAIDs. There were no significant findings on clinical examination apart from pallor and tachycardia (Heart rate - 110/minute). His hemoglobin was 6.8 gm/dl and hematocrit was 20%. Coagulation parameters were normal. The nasogastric aspirate was clear. An upper GI endoscopy revealed normal esophagus and stomach. The duodenal bulb was deformed but no active ulcer was seen. Few clots were seen adherent to the postbulbar mucosa that appeared grossly normal (Figure 1). The patient rebled the next day. A repeat endoscopy showed an actively bleeding vessel in the postbulbar duodenum. The surrounding mucosa was normal (Figure 2). These findings were suggestive of a DL of the duodenum. A peri and intralesional injection of 1:10,000 adrenaline solution controlled the bleeding. Subsequent recovery was uneventful. The video recording of the first endoscopy was reviewed

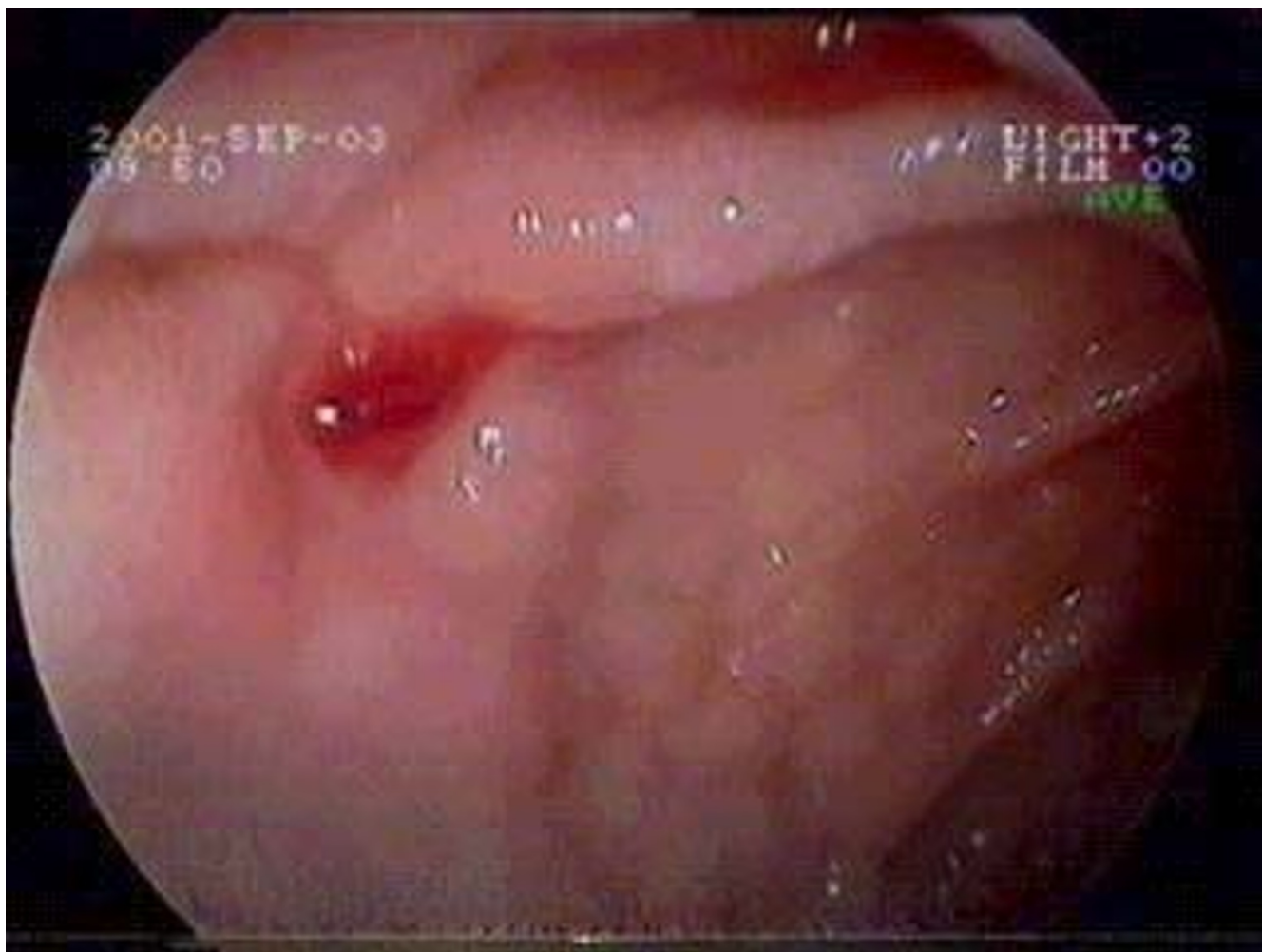

Figure 1

DL of the duodenum. Note the deformed duodenal bulb with small clot adherent to the mucosa in the postbulbar area. The mucosa is normal and there is no evidence of any duodenal ulcer. Lesion was missed on (first) endoscopy because it was covered with the tiny clot and the surrounding mucosa was normal.

focussing on the lesion bearing segment (the post bulbar duodenum). The lesion escaped our attention possibly because it was covered with a tiny clot and the surrounding mucosa was normal. Patient continues to be well at a follow-up of eight months. Repeat endoscopy performed one month and six months after his discharge showed normal mucosa in the involved area.

Case 2

A 25-year-old female presented with a one year history of intermittent episodes of melena. There was no history of acid peptic disease, NSAID intake or chronic liver disease. There were no significant findings on clinical examination apart from severe pallor and tachycardia. Laboratory investigations revealed hemoglobin of 1.6 gm/dL and he-

matocrit of 5%. Other hematological and biochemical investigations were within normal limits. Upper GI endoscopy showed fresh blood and persistent oozing from a punctate area in the roof of the duodenal bulb. The surrounding duodenal mucosa was normal with no deformity of the duodenal bulb (Movie 1; see additional file 1). A diagnosis of DL of the duodenum was made. The esophagus, stomach and second part of duodenum were normal. The lesion was injected with 1:10,000 adrenaline solution following which the bleeding stopped. Patient received 6 units of packed cell transfusion. Subsequent recovery was uneventful and bleeding has not recurred in a follow up of seven months.

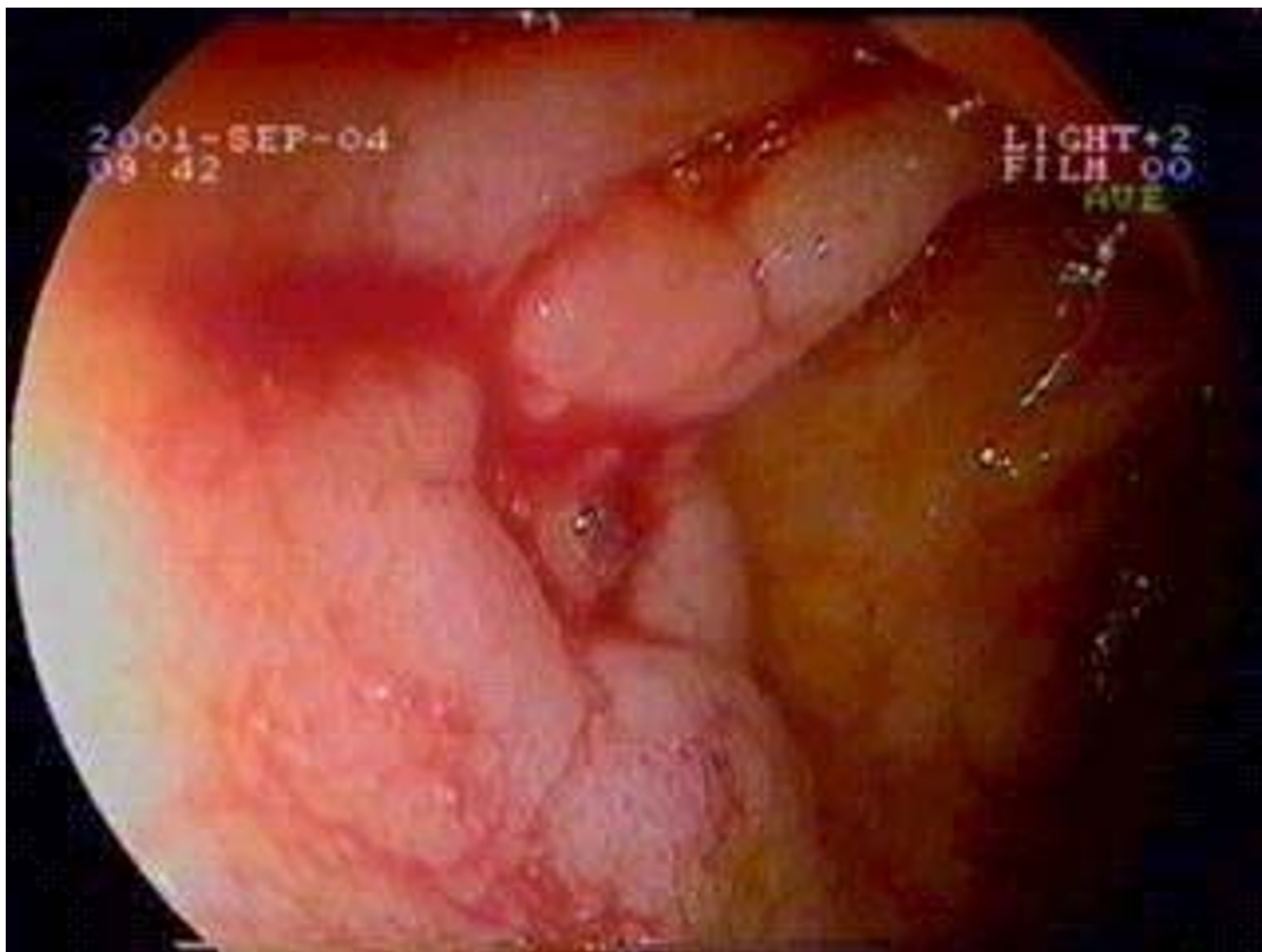


Figure 2

DL of the duodenum. An actively bleeding DL in the postbulbar duodenum (same case shown in Figure 1). Repeat endoscopy, 24 hours later, immediately following rebleeding showed actively bleeding vessel in postbulbar duodenum. The surrounding mucosa is edematous because of adrenaline injection.

Discussion

Approximately 75 – 95 % DLs are found within 6 cms of the gastro-esophageal junction predominantly on the lesser curvature which is possibly related to the peculiar vascular anatomy of the stomach in this region [1]. In one large series from a tertiary care centre in India, of 900 cases of upper GI bleeding, DL was the cause in only six (0.67%) cases with the lesion being located within 6 cms of the GE junction in all cases [2]. Extragastric DLs are uncommon. In a review of over 100 cases of DLs, Veldhuyzen found no lesion of the duodenum [3]. Duodenal DL is rare and was reported for the first time in 1988 [4]. Similar lesions have also been described in the esophagus [5,6], jejunum, colon and rectum [6–8]. Extragastric DLs have been identified more frequently in recent years be-

cause of increased awareness of the condition [6,7]. In a large series of 89 patients with DLs, in a third of cases the lesions were extragastric. Duodenum was the commonest location(18%) of extragastric DLs followed by colon(10%) and jejunum(2%) and esophagus(2%) [6]. The pathology of the lesion is essentially the same throughout the gastrointestinal tract and it is caused by an abnormally large calibre persistent tortuous submucosal artery [7].

The endoscopic criteria proposed to define DL are: 1) Active arterial spurting or micropulsatile streaming from a minute mucosal defect or through normal surrounding mucosa, 2) Visualization of a protruding vessel with or without active bleeding within a minute mucosal defect or through normal surrounding mucosa, and 3) Fresh,

densely adherent clot with a narrow point of attachment to a minute mucosal defect or to normal appearing mucosa [8]. The lesion in the first patient was missed initially. This was attributed to the tiny clot obscuring the lesion that had stopped bleeding. The surrounding normal mucosa and the deformed duodenal bulb misled us further. The correct diagnosis could be made only when endoscopy was carried out 24 hrs later during another episode of active bleeding. The endoscopic finding in the second patient i.e. punctate oozing from an otherwise normal mucosa is also quite characteristic of duodenal DL. We presume it would have been difficult to diagnose the lesion if the patient were not actively bleeding during the procedure.

DL is an inherently difficult lesion to diagnose and should be considered during evaluation of any patient with unexplained, recurrent, massive GI bleeding. History of NSAID intake, acid peptic disease or alcohol abuse is usually absent [1,4]. The diagnosis at initial endoscopy in earlier reports was in only half the cases. A third of lesions were diagnosed at repeat endoscopy, the remainder identified either intraoperatively or on angiography. In recent series the identification at initial endoscopic examination has been in more than 90% of cases. This is not only due to early endoscopy which helps in identification but also due to increased awareness of the pathology and careful endoscopy which are the key to accurate diagnosis [1].

The lesions in both the patients were amenable to endoscopic adrenaline injection. Therapeutic endoscopy has evolved as the modality of choice for the initial treatment of DLs [1,6,9,10]. Adrenaline injection has been used as sole therapy or in combination with other endoscopic modalities. The other endoscopic hemostatic techniques apart from adrenaline injection include bipolar and monopolar electrocoagulation, heater probe, laser photocoagulation, injection sclerotherapy, hemoclipping and endoscopic band ligation (EBL)[1,6,9]. The electro and thermocoagulation methods carry a risk of transmural injury in thin walled organs like duodenum and are better suited for gastric DL [1]. Some Japanese groups have also suggested the use of vascular clips as an effective and safe method of hemostasis in DLs in thin walled organs like duodenum. The normal surrounding mucosa in a DL makes it an adequate target for hemoclipping [11,12]. Recently EBL has also been reported as an effective, safe, simple and inexpensive method for the treatment of DL [10,13]. The bleeding vessel with the surrounding mucosa is sucked into the lumen of the ligator and the preloaded band is fired which strangulates the bleeding vessel and stops bleeding. Nikolaidis et al have reported successful control of bleeding in 96% (n = 22/23) patients with Dieulafoy like lesions who were treated by EBL [10]. Chung et al in a comparative study of efficacy of hemo-

static methods in patients with DLs reported that mechanical methods for hemostasis like EBL and hemoclipping were more superior to injection methods in control of bleeding as well as preventing recurrent bleeding [14]. Surgical ligation is an alternative that can be considered for failed endoscopic therapy and in the present day scenario is required in less than 5% cases [1,4,10]. Angiography and embolisation is another modality which has been reported in patients with active bleeding who are not amenable to endoscopic therapy and are poor surgical candidates [15].

Conclusions

In conclusion, duodenal DL is an uncommon but important cause of recurrent and significant upper GI bleeding. Increased awareness and early endoscopy during a bleeding episode are essential for accurate diagnosis. Endoscopic adrenaline injection is an important technique to control the bleeding.

Lists of abbreviations used

DL – Dieulafoy's lesion

GI – Gastrointestinal

NSAID – Non steroidal anti-inflammatory drug

EBL – Endoscopic band ligation

Competing interests

None to declare

Authors' contributions

MI was involved in the diagnosis and management of both the cases and in guiding author 2 in writing the manuscript

GW was involved in compiling the details of the patients and actual drafting of manuscript.

Both authors read and approved the final manuscript.

Additional material

Additional File 1

Actively bleeding DL of the duodenum. Actively bleeding DL of the duodenum. Note the normal duodenal mucosa with no deformity of the bulb.
Click here for file

[<http://www.biomedcentral.com/content/supplementary/1471-230X-3-2-S1.mpg>]

Acknowledgements

Written consent was obtained from the patients for publication of study.

References

1. Al-Mishlab T, Amin AM and Ellul JM **Dieulafoy's lesion: an obscure cause of GI bleeding.** *J R Coll Surg Edinb* 1999, **44**:222-225
2. Arora A, Mehrotra R, Patnaik PK, Pande G, Ahlawat S and Bhargava DK **Dieulafoy's lesion: a rare cause of massive upper gastrointestinal haemorrhage.** *Trop Gastroenterol* 1991, **12**:25-30
3. Veldhuyzen van Zanten SJ, Bartelsman JF, Schipper ME and Tytgat GN **Recurrent massive hematemesis from Dieulafoy vascular malformation – a review of 101 cases.** *Gut* 1986, **27**:213-222
4. McClave SA, Goldschmid S, Cunningham JT and Boyd WWP Jr **Dieulafoy's cirroid aneurysm of the duodenum.** *Dig Dis Sci* 1988, **33**:801-805
5. Ertekin C, Barbaros U, Taviloglu K, Guloglu R and Kasoglu A **Dieulafoy's lesion of esophagus.** *Surg Endosc* 2002, **16**:219
6. Norton ID, Petersen BT, Sorbi D, Balm RK, Alexander GL and Gostout CJ **Management and long-term prognosis of Dieulafoy lesion.** *Gastrointest Endosc* 1999, **50**:762-767
7. Gadenstatter M, Wetscher G, Crookes PF, Mason RJ, Schwab G and Pointner R **Dieulafoy's disease of the large and small bowel.** *J Clin Gastroenterol* 1998, **27**:169-172
8. Dy NM, Gostout CJ and Balm RK **Bleeding from the endoscopically-identified Dieulafoy lesion of the proximal small intestine and colon.** *Am J Gastroenterol* 1995, **90**:108-111
9. Goldenberg SP, DeLuca VA Jr and Marignani P **Endoscopic treatment of Dieulafoy's lesion of the duodenum.** *Am J Gastroenterol* 1990, **4**:452-454
10. Nikolaidis N, Zezos P, Giouleme O, Budas K, Marakis G, Paroutoglou G and Eugenidis N **Endoscopic band ligation of Dieulafoy-like lesions in the upper gastrointestinal tract.** *Endoscopy* 2001, **33**:754-760
11. Hokama A, Ikema R, Hanashiro K, Kinjo F and Saito A **Endoscopic hemoclippping for duodenal Dieulafoy's lesion.** *Am J Gastroenterol* 1996, **91**:2450
12. Sueoka N, Koizumi N, Inokuchi K and Wakabayashi I **Combined endoscopic clipping and ethanol injection for treatment of Dieulafoy's lesions in the duodenum.** *Gastrointest Endosc* 1997, **46**:574-575
13. Ertekin C, Taviloglu K, Barbaros U, Guloglu R and Dolay K **Endoscopic band ligation: alternative treatment method in non-variceal upper gastrointestinal hemorrhage.** *J Laparoendosc Adv Surg Tech A* 2002, **12**:41-45
14. Chung IK, Kim EJ, Lee MS, Kim HS, Park SH, Lee MH, Kim SJ and Cho MS **Bleeding Dieulafoy's lesions and the choice of endoscopic method: comparing the hemostatic efficacy of mechanical and injection methods.** *Gastrointest Endosc* 2000, **52**:721-724
15. Katz PO and Salas L **Less frequent causes of upper gastrointestinal bleeding.** *Gastroenterol Clin North Am* 1993, **22**:875-889

Pre-publication history

The pre-publication history for this paper can be accessed here:

<http://www.biomedcentral.com/1471-230X/3/2/prepub>

Publish with **BioMed Central** and every scientist can read your work free of charge

"BioMed Central will be the most significant development for disseminating the results of biomedical research in our lifetime."

Sir Paul Nurse, Cancer Research UK

Your research papers will be:

- available free of charge to the entire biomedical community
- peer reviewed and published immediately upon acceptance
- cited in PubMed and archived on PubMed Central
- yours — you keep the copyright

Submit your manuscript here:
http://www.biomedcentral.com/info/publishing_adv.asp

